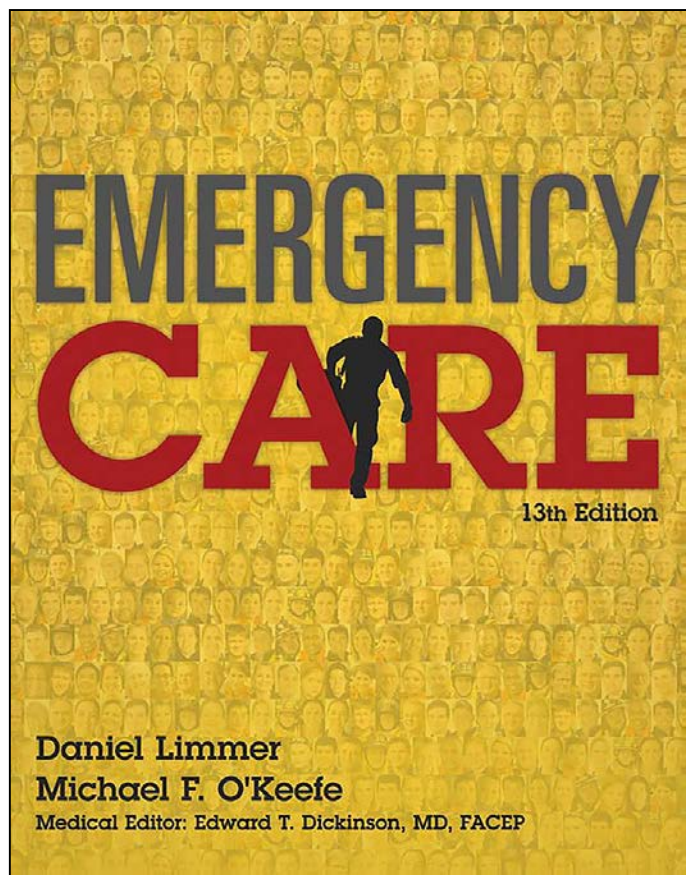


# Emergency Care

THIRTEENTH EDITION



## CHAPTER 28

### Musculoskeletal Trauma

# Multimedia Directory

---

[Slide 55      Splinting – Immobilization of a Long Bone Fracture Video](#)

[Slide 86      Hip Fractures Animation](#)

# Topics

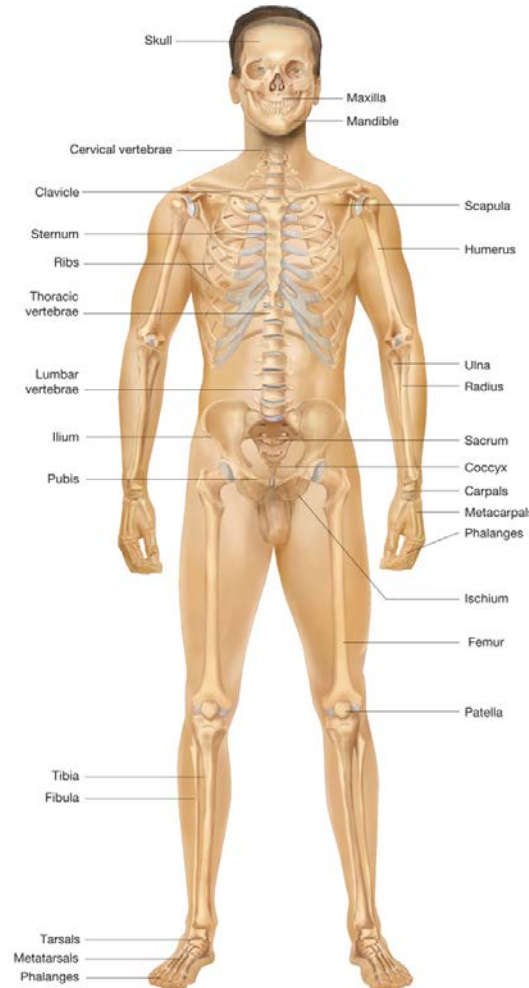
---

- Musculoskeletal System
- General Guidelines for Emergency Care
- Emergency Care of Specific Injuries

# Musculoskeletal System

# Musculoskeletal System

- Bones
  - Framework
- Joints
  - Bending
- Muscles
  - Movement



*continued on next slide*

# Musculoskeletal System

---

- Cartilage
  - Flexibility
- Ligaments
  - Connect bone to bone
- Tendons
  - Connect muscle to bone

# Anatomy of Bone

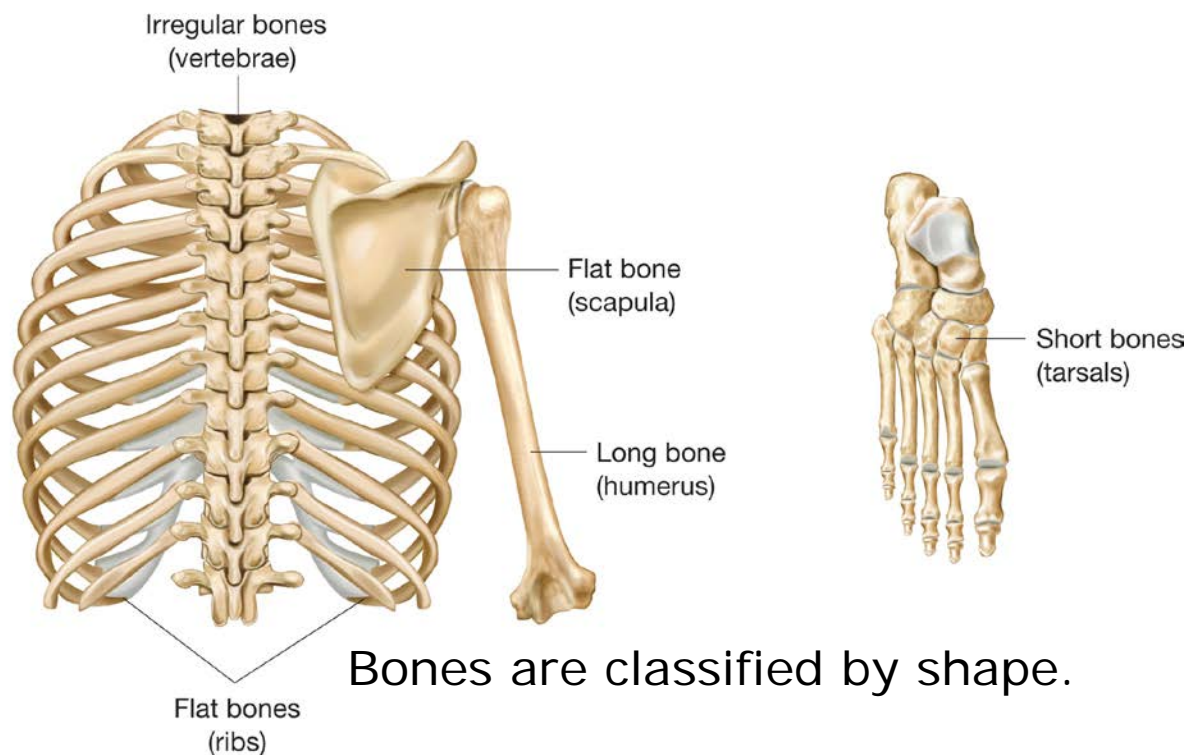
---

- Bones
  - Formed of dense connective tissues
  - Vascular and susceptible to bleeding on injury
  - Covered by periosteum

# Anatomy of Bone

- Classification of shape

- Irregular
- Long
- Short
- Flat





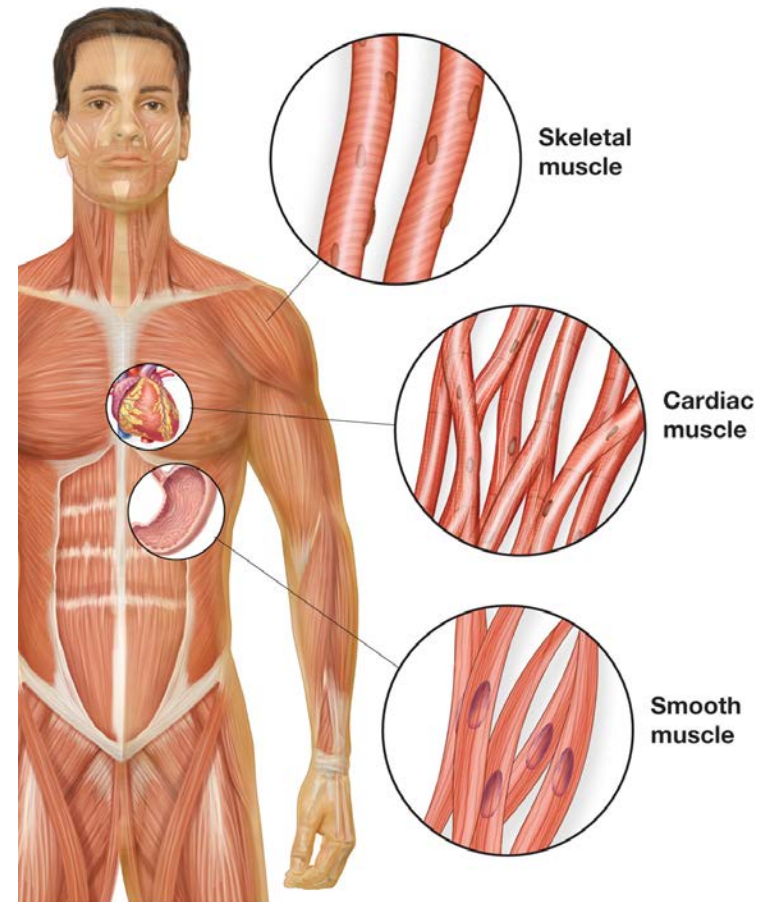
# Self-Healing Nature of Bone

---

- Break causes soft tissue swelling and a blood clot in the fracture area.
- Interruption of blood supply causes cells to die at injury site.
- Cells further from fracture rapidly divide forming tissue that heals the fracture and develops into new bone.

# Muscles

- Kinds of muscles
  - Skeletal (voluntary)
  - Smooth (involuntary)
  - Cardiac (myocardial)



# Cartilage

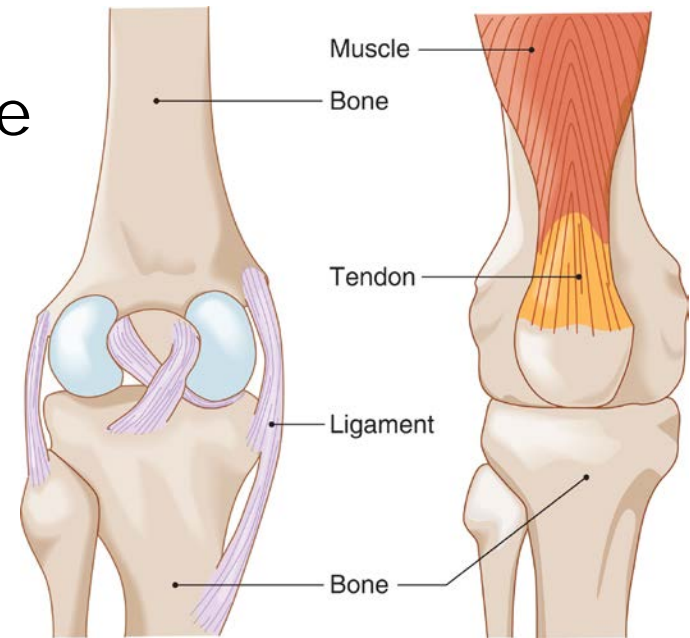
---

Cartilage helps form flexible structures of the body.

# Ligaments

Ligaments support joints by attaching bone ends to allow for stable range of motion

BLB = bone-ligament-bone

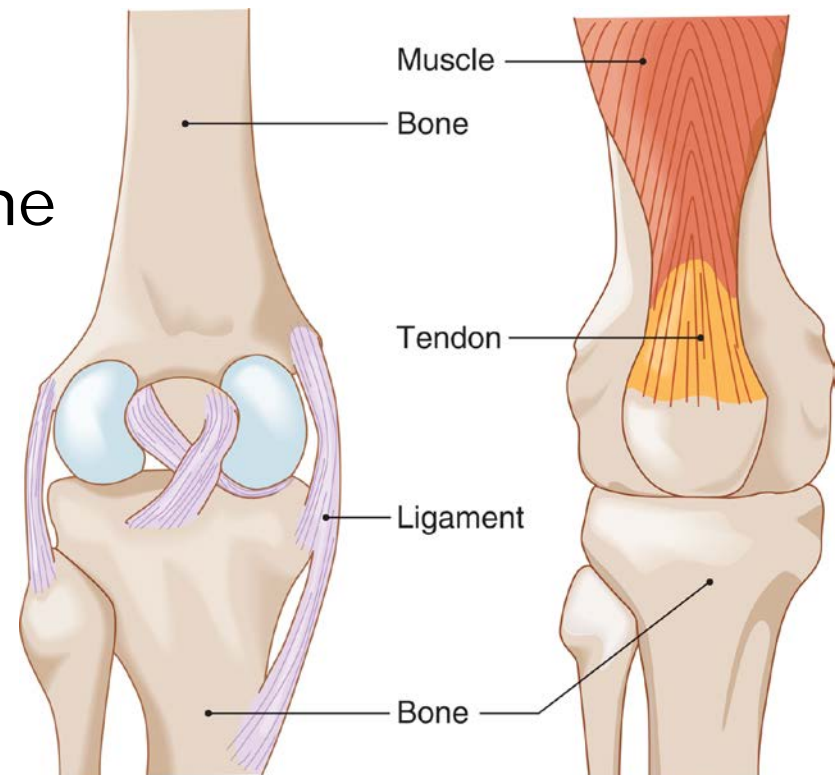


Tendons tie muscle to bone. Ligaments tie bone to bone.

# Tendons

Tendons allow for the power of movement across joints.

MTB = muscle-tendon-bone



Tendons tie muscle to bone. Ligaments tie bone to bone.

# General Guidelines for Emergency Care

# Mechanisms of Musculoskeletal Injury

---

- Direct force
- Indirect force
- Twisting (rotational) force

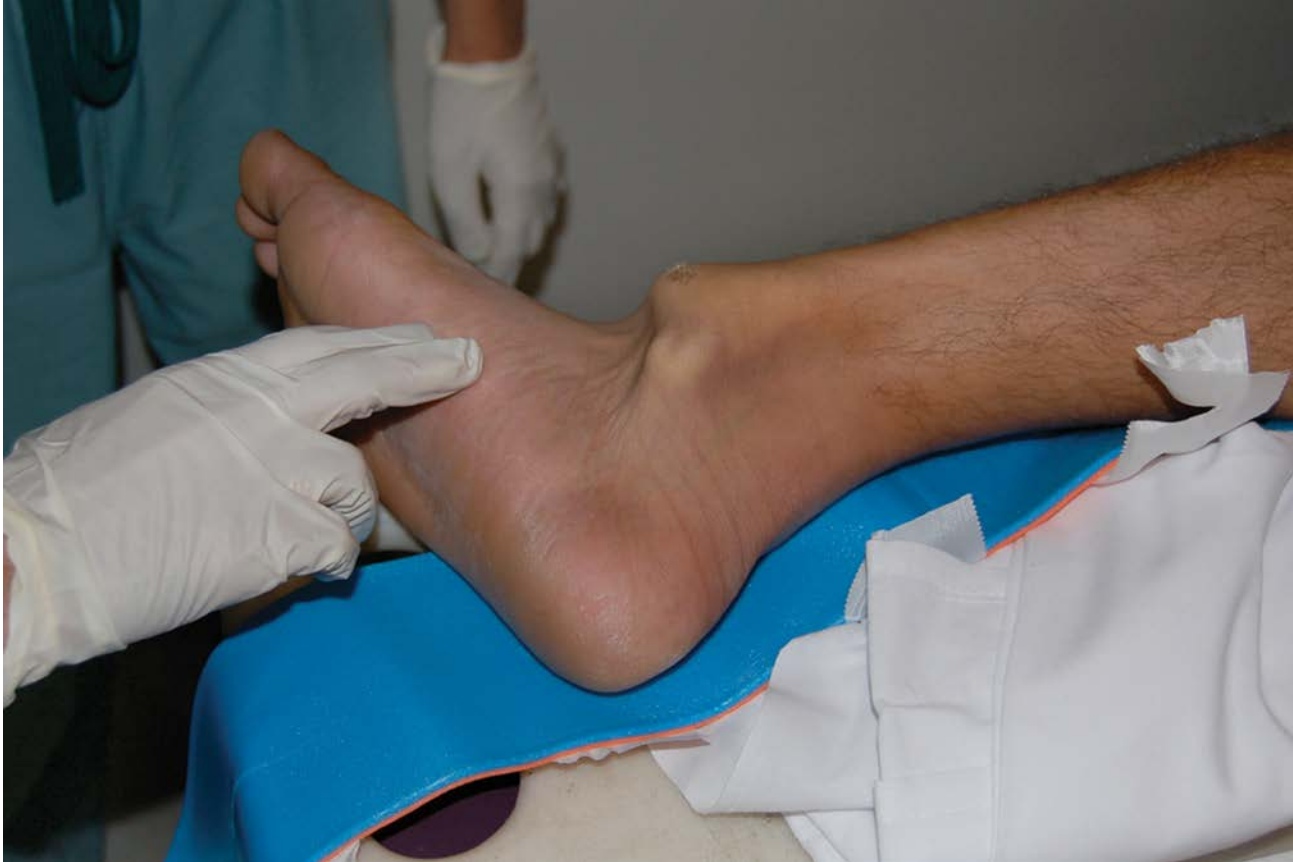# Injury to Bones and Connective Tissue

---

- Fracture
  - Any break in a bone, open or closed
  - Comminuted
    - Broken in several places
  - Greenstick
    - Incomplete break
  - Angulated
    - Bent at angle



# Injury to Bones and Connective Tissue



Closed fracture. © *Edward T. Dickinson, MD*

# Injury to Bones and Connective Tissue

---

- Dislocation
  - "Coming apart" of a joint
- Sprain
  - Stretching and tearing of ligaments
- Strain
  - Overstretching or overexertion of muscle

*continued on next slide*

# Injury to Bones and Connective Tissue

---

- Not all injuries can be confirmed as a fracture in the field.
- Splinting an extremity with a suspected fracture helps prevent blood loss from bone tissues.

# Assessment of Musculoskeletal Injuries

---

- Rapidly identify and treat life-threatening conditions.
- Be alert for injuries besides grotesque wound.
- Cut or remove patient's clothing to complete examination according to the environment and severity of situation.

# Compartment Syndrome

---

- Severe swelling in the extremity as a result of fracture
- Progression
  - Fracture or crush injury causes bleeding and swelling in extremity.
  - Pressure and swelling become so great the body can no longer perfuse the tissues against pressure.

*continued on next slide*

# Compartment Syndrome

---

- Progression
  - Cellular damage occurs, causing additional swelling.
  - Blood flow to the area is lost.
    - Limb may also be lost if the pressure is not relieved.

# Patient Assessment

---

- Pain and tenderness
- Deformity and angulation
- Grating (crepitus)
- Swelling and bruising
- Exposed bone ends
- Joints locked into position
- Nerve/blood vessel compromise
- Compartment syndrome

*continued on next slide*

# Patient Assessment

---

- Six P's of assessment
  - **P**ain or tenderness
  - **P**allor (pale skin)
  - **P**arasthesia (pins and needles)
  - **P**ulses diminished or absent
  - **P**aralysis
  - **P**ressure



# Think About It

---

- Do my patient's musculoskeletal injuries add up to serious multiple trauma?
- Does my patient have circulation, sensation, and motor function distal to the suspected fracture or dislocation?

# Patient Care

---

- Take Standard Precautions.
- Perform primary assessment.
- During secondary assessment, apply cervical collar if you suspect spine injury.

# Patient Care

---

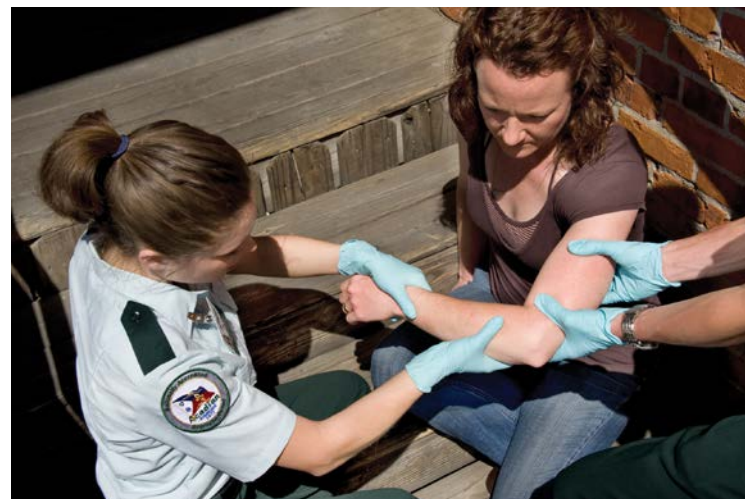- Splint any suspected extremity fractures after treating life-threatening conditions.
- Cover open wounds with sterile dressings.

# Splinting

- Advantages
  - Minimizes movement of disrupted joints and broken bone ends
  - Prevents additional injury to soft tissues
    - Nerves, arteries, veins, muscles
  - Decreases pain
  - Minimizes blood loss
  - Can prevent a closed fracture from becoming an open fracture

# Realignment of the Deformed Extremity

- Assists in restoring effective circulation to extremity and to fit it to splint
- If not realigned, splint may be ineffective, causing increased pain and possible further injury.



# Realignment of the Deformed Extremity

---

- If not realigned, increased chance of nerves, arteries, and veins being compromised
- Increased pain is only momentary.

*continued on next slide*

# Realignment of the Deformed Extremity

---

- Guidelines
  - One EMT grasps distal extremity while partner place one hand above and below injury site.
  - Partner supports first EMT who creates gentle manual traction in direction of long axis of extremity.
  - If no resistance is felt, maintain gentle traction until extremity is properly aligned and splinted.

# Strategies for Splinting



Splints and accessories for musculoskeletal injuries.



# Strategies for Splinting

---

- Effective splinting may require some ingenuity.
- Three types available on EMS units
  - Rigid splints
  - Formable splints
  - Traction splints

# Strategies for Splinting

---

- Care for life-threatening problems first.
- Expose injury site.
- Assess distal CSM.
- Align long-bone injuries to anatomical position.
- Do not push protruding bones back into place.

*continued on next slide*

# Strategies for Splinting

---

- Immobilize both injury site and adjacent joints.
- Choose splinting method based on severity of condition and priority decision.
- Apply splint before moving patient to stretcher or other location if possible.
- Pad voids.

# Hazards of Splinting

---

- "Splinting patient to death"
  - Splinting before life-threatening conditions addressed
- Not ensuring ABC's
- Too tight
  - Compresses soft tissues
- Too loose
  - Allows too much movement
- Splinting in deformed position

# Treatment: Splinting Long-Bone and Joints



First Take Standard Precautions.

1. Manually stabilize the injured limb, in this case an injured elbow.

# Splinting Long-Bone and Joint Injuries

---

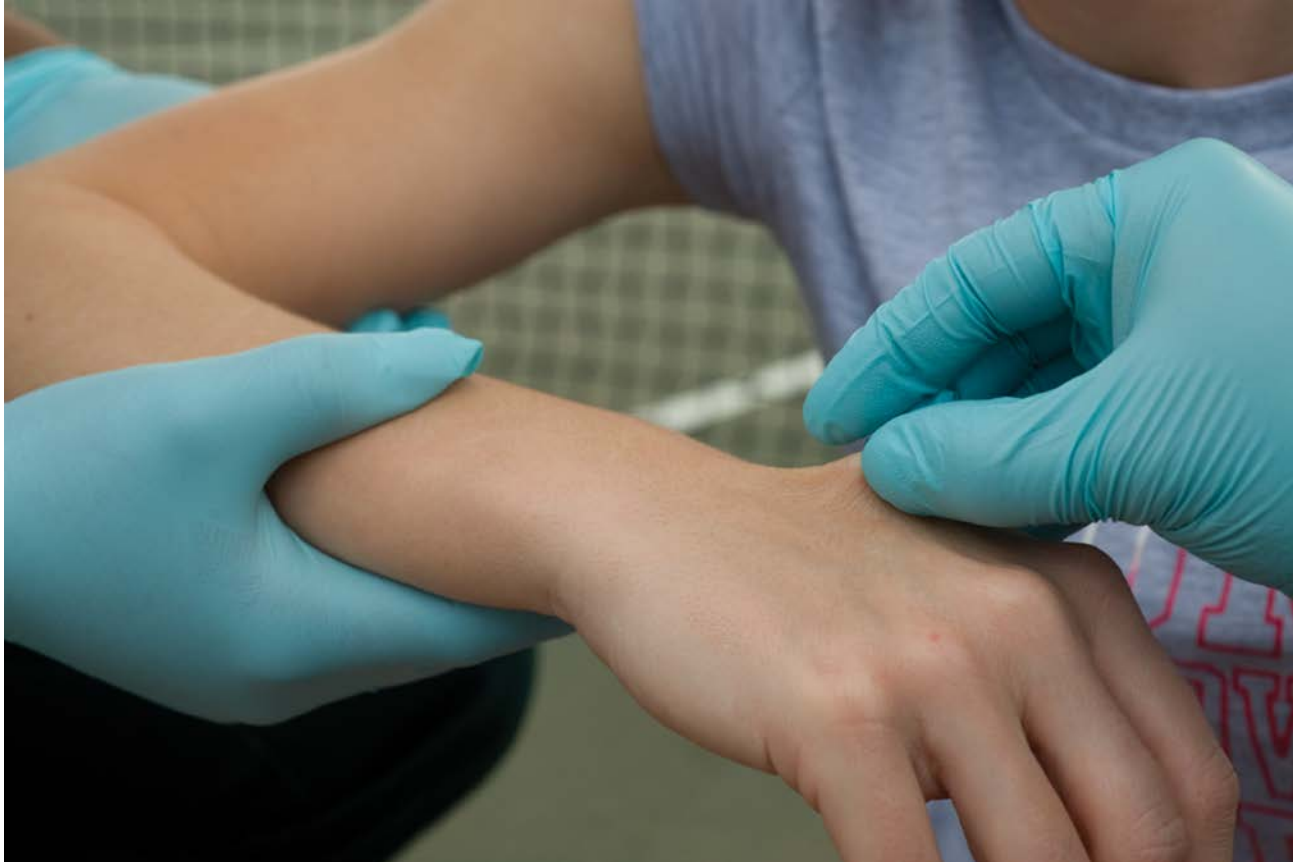- Take appropriate Standard precautions.
- If possible, expose area to be splinted.
- Manually stabilize injury site.

# Splinting Long-Bone and Joint Injuries

---

- Assess circulation, sensation, and motor function.
- Realign injury if deformed or if distal extremity is cyanotic or pulseless.

# Treatment: Splinting Long-Bone and Joints



2. Assess distal pulse, motor function, and sensation (CSM).



# Splinting Long-Bone and Joint Injuries

---

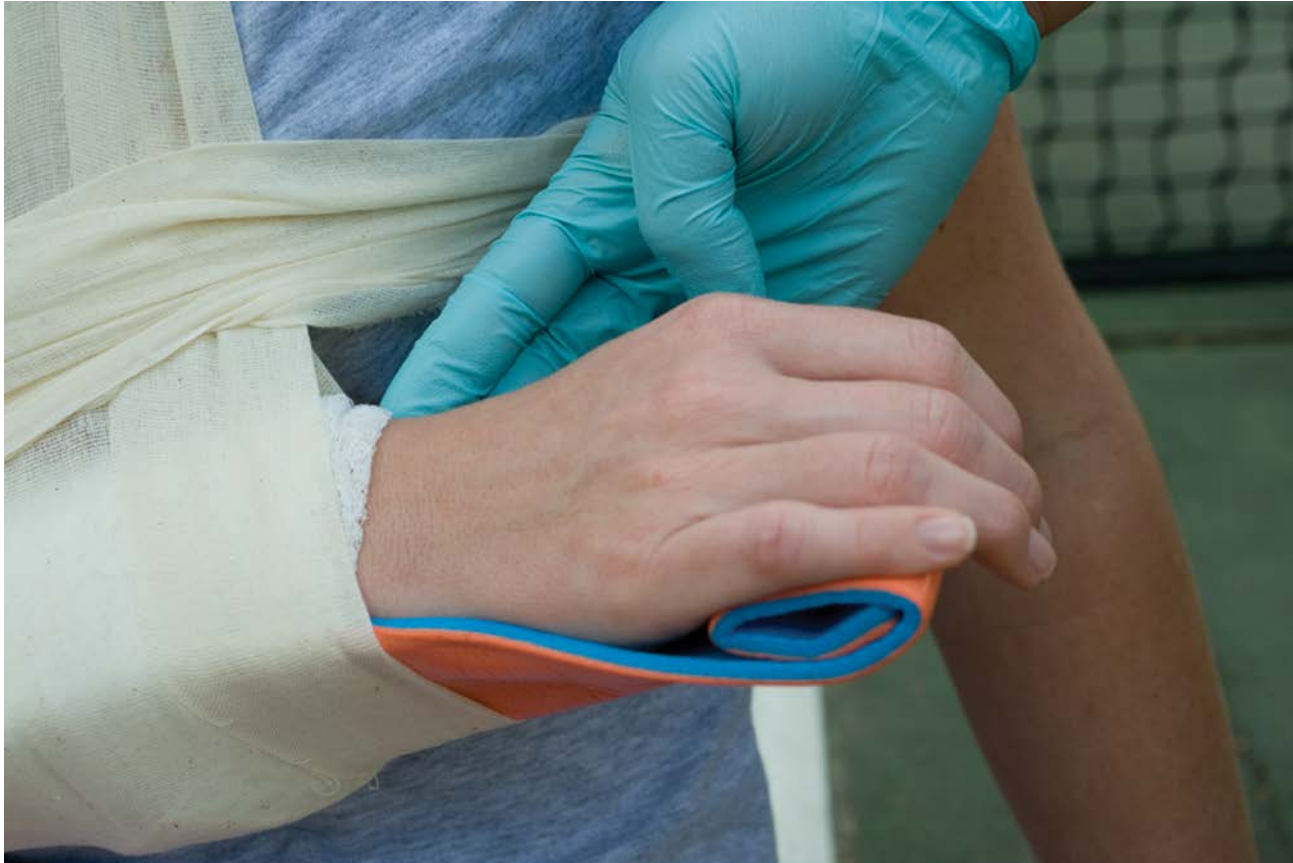- Measure or adjust splint.
  - Move it into position.
- Apply and secure splint to immobilize injury site, adjacent joints.
- Reassess CSM distal to injury.

# Treatment: Splinting Long-Bone and Joints



4. Secure the splint.

# Treatment: Splinting Long-Bone and Joints



5. Reassess distal CSM.

# Traction Splint

---

- Counteracts muscle spasms and greatly reduces pain
- Types
  - Bipolar
  - Unipolar
- Amount of traction applied should be roughly 10 percent of patient's body weight
  - Not exceeding 15 pounds

*continued on next slide*

# Traction Splint

---

- Take Standard Precautions and, if possible, expose the area to be splinted.
- Manually stabilize the leg and apply manual traction.
- Assess CSM distal to the injury.
- Adjust the splint to the proper length, and position it at or under the injured leg.

*continued on next slide*

# Traction Splint

---

- Apply the proximal securing device (ischial strap).
- Apply the distal securing device (ankle hitch).
- Apply mechanical traction.
- Position and secure support straps.

*continued on next slide*

# Traction Splint

---

- Reevaluate the proximal and distal securing devices, and reassess CSM distal to the injury.
- Secure the patient's torso and the traction splint to a long spine board to immobilize the hip and to prevent movement of the splint.



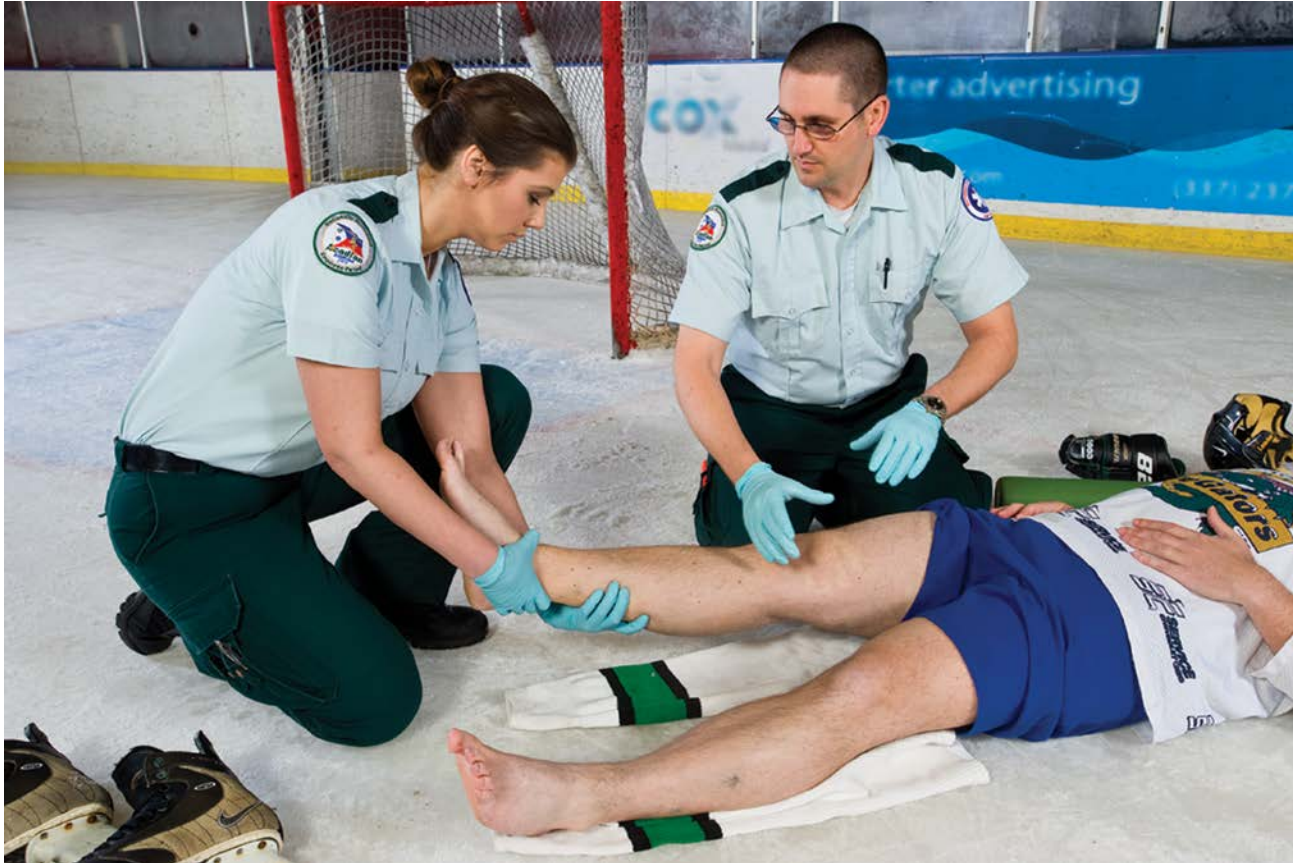# Treatment: Traction Splint



1. Take Standard Precautions. **NOTE:** *Assess the distal circulation, sensation, and motor function both before and after immobilizing or splinting an extremity.*

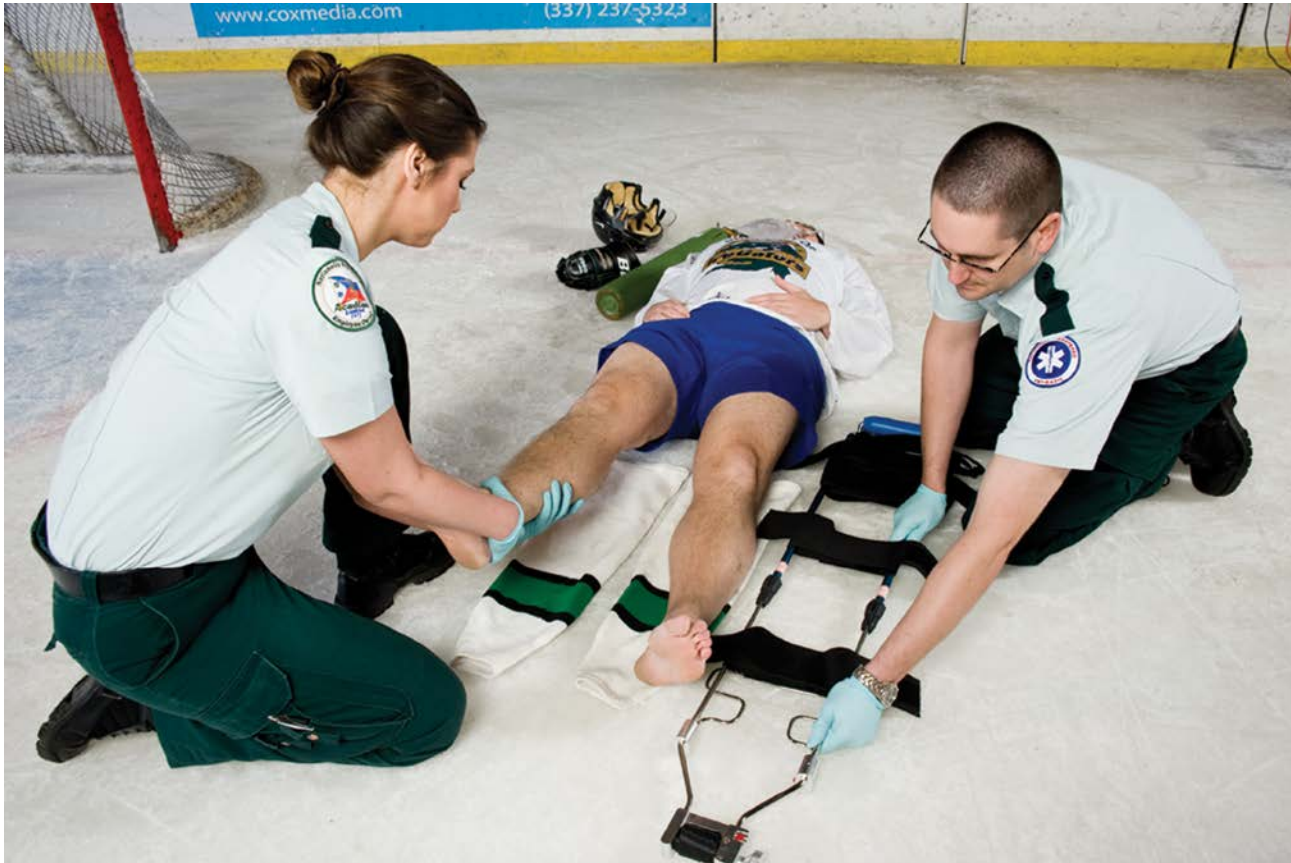

# Treatment: Traction Splint



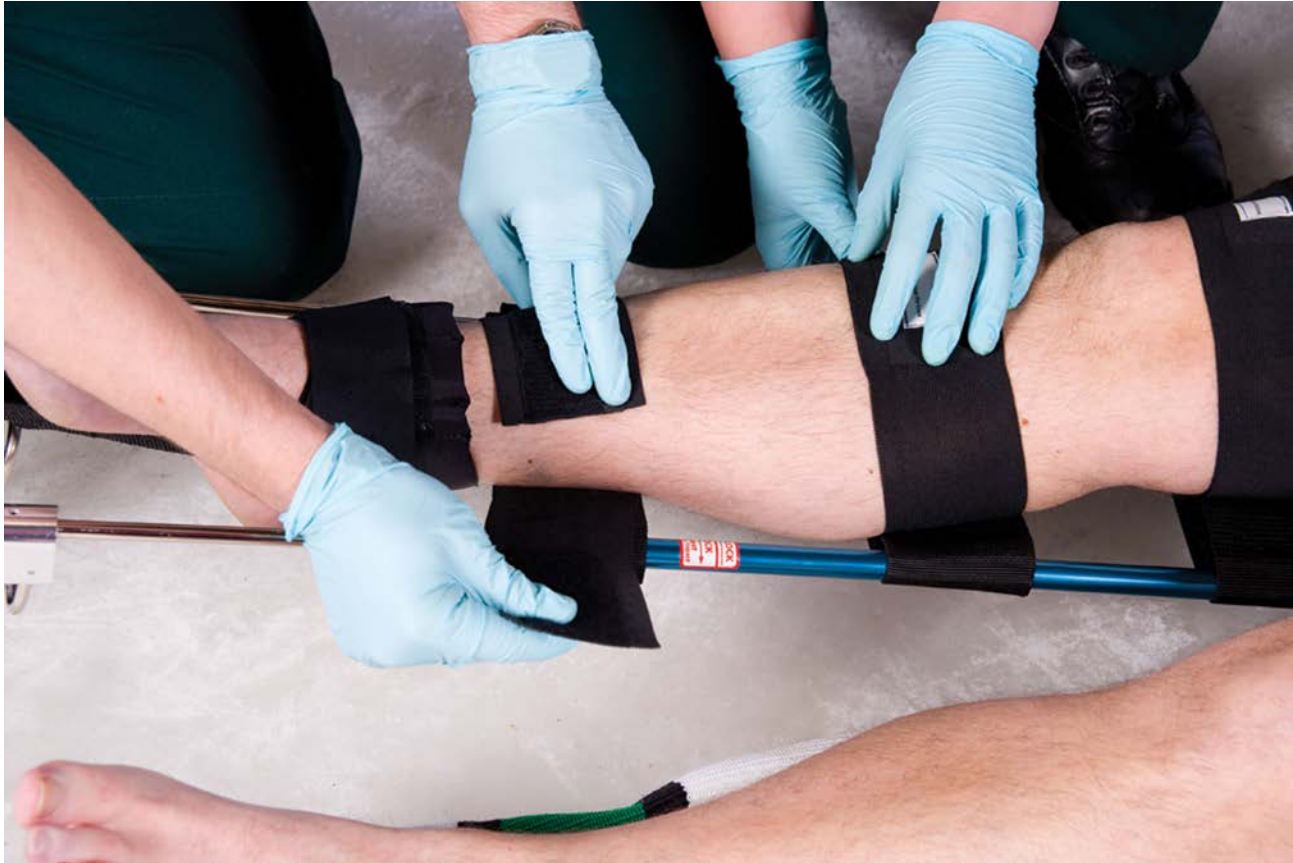2. Manually stabilize the injured leg.

# Treatment: Traction Splint



4. Adjust the splint to the proper length, and position it next to the injured leg.

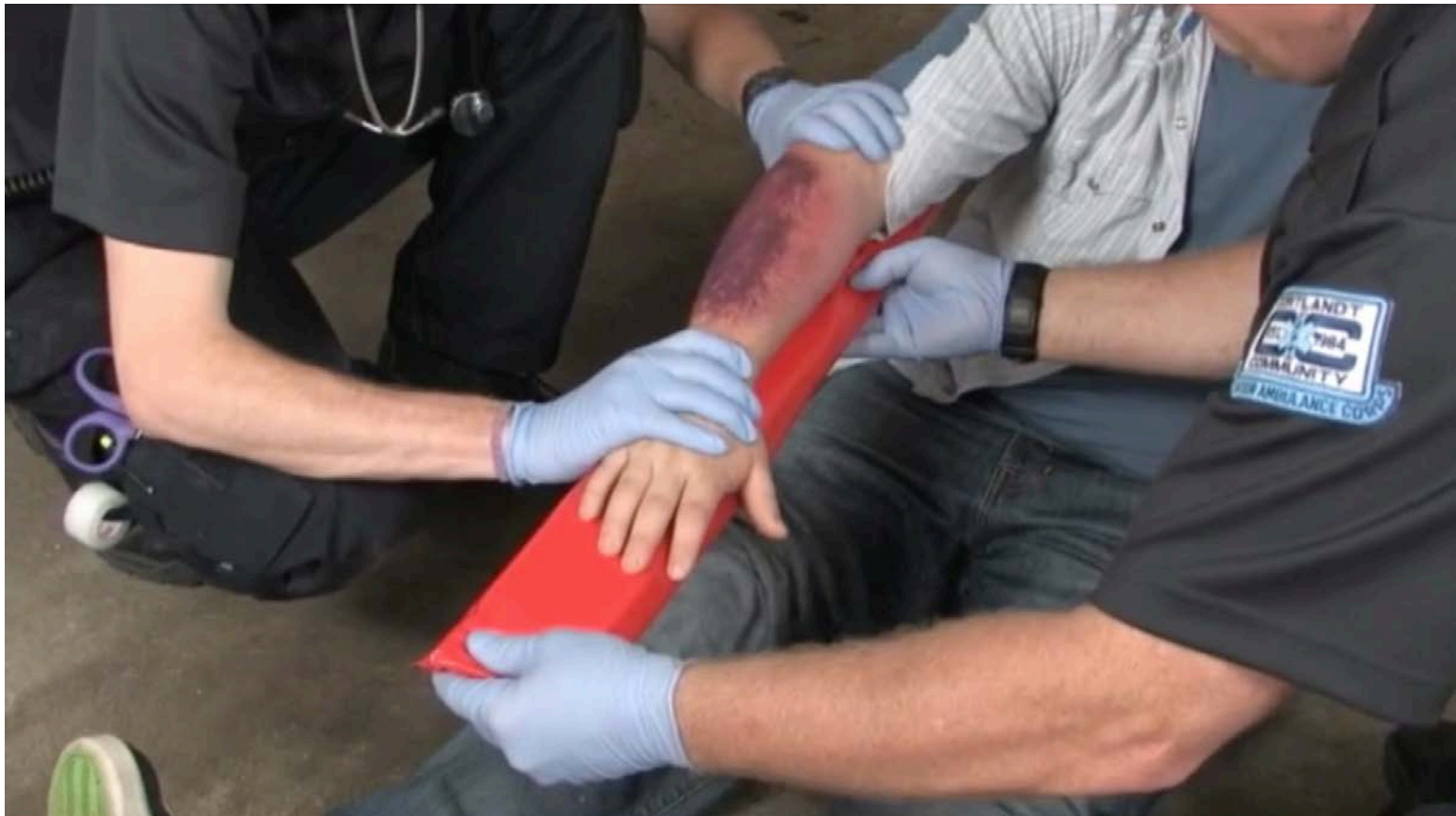# Treatment: Traction Splint



8. Secure support straps, as appropriate.



# Splinting – Immobilization of a Long Bone Fracture Video



Click on the screenshot to view a video on the subject of splinting a long bone injury.

[Back to Directory](#)

# Emergency Care of Specific Injuries

# Shoulder Girdle Injuries

---

- Patient assessment
  - Pain in shoulder
  - Dropped shoulder
  - Severe blow to back over scapula

*continued on next slide*

# Shoulder Girdle Injuries

---

- Patient care
  - Assess distal CSM.
  - Use sling and swathe.
  - If evidence of anterior dislocation of head of humerus, place pillow between patient's arm and chest.
  - Do not attempt to straighten or reduce.
  - Reassess distal CSM.

# Pelvic Injuries

- Patient assessment
  - Pain in pelvis, hips, groin, or back
  - Pain when pressure applied to iliac crests
  - Cannot lift legs when lying on back
  - Lateral rotation of foot
  - Unexplained pressure in bladder
  - Bleeding from urethra, rectum, or vaginal opening

*continued on next slide*



# Pelvic Injuries

---

- Patient care
  - Move patient as little as possible.
  - Determine CSM distal to injury site.
  - Straighten lower limbs to anatomical position.
  - Stabilize lower limbs.
  - Assume spinal injuries.

*continued on next slide*

# Pelvic Injuries

---

- Patient care
  - Reassess distal CSM.
  - Care for shock, provide high-concentration oxygen.
  - Transport patient as soon as possible.
  - Monitor vital signs.

# Pelvic Wrap

---

- Commercially available devices
  - Can also use a sheet
- Applied to patients who have pelvic deformity or instability whether or not signs of shock are present

# Pelvic Wrap



A commercial pelvic splint.

# Pelvic Wrap



To devise a pelvic wrap, lay a sheet, folded flat, approximately 10 inches wide onto the backboard.

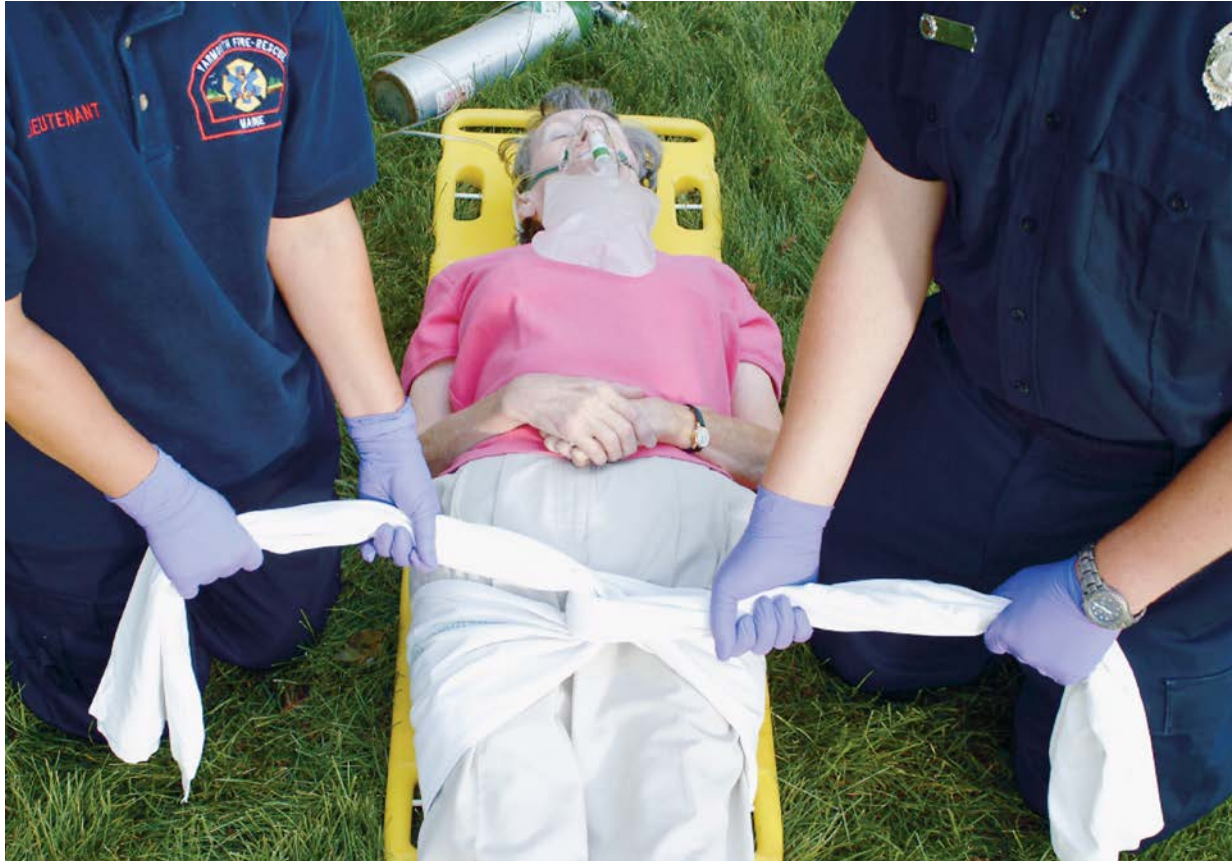

# Pelvic Wrap



Bring the sides of the sheet together.

# Pelvic Wrap



Tie the sheet firmly without overcompression to complete the pelvic wrap.

# Hip Dislocation

---

- Patient assessment
  - Anterior hip dislocation
  - Posterior hip dislocation
    - Rotation of leg inward and knee is bent.
    - Foot may hang loose and unable to flex the foot or lift toes.
    - Lack of sensation in limb

*continued on next slide*



# Hip Dislocation

---

- Patient care
  - Assess distal CSM.
  - Move patient onto long spine board.
  - Immobilize limb with pillows and blankets.
  - Secure patient to spine board.

*continued on next slide*

# Hip Dislocation

---

- Patient care
  - Reassess distal CSM.
  - Care for shock.
  - Transport, monitor vital signs, check for nerve and circulation impairment.

# Geriatric Note

---

- Direct force and twisting forces can cause a hip fracture.
  - MVC or falls
- Older adults are more susceptible to this type of injury because of their brittle bones or weakness from various diseases.

# Hip Fracture

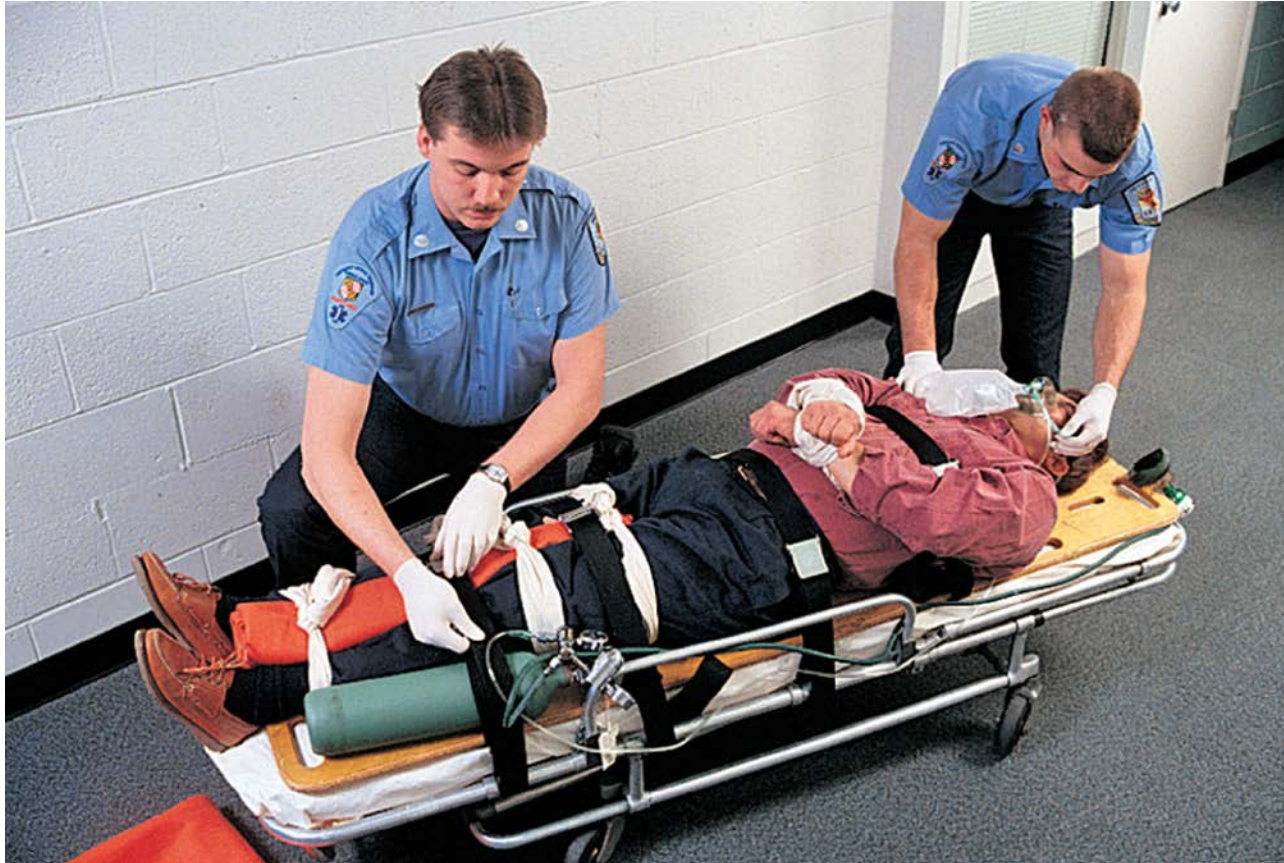- Patient assessment
  - Pain is localized.
  - Surround tissues are discolored.
  - Swelling may be evident.
  - Unable to move limb while on back
  - Unable to stand
  - Foot on injured side turns outward.
  - Injured limb appears shorter.

*continued on next slide*

# Hip Fracture

- Patient care
  - Place folded blanket between patient's legs, and bind legs together with wide straps, or wide cravats.
  - Use thin splints to push cravats or straps under patient at natural voids and readjust so they will pass across the chest, the abdomen just below the belt, below the crotch, above and below the knee, and at the ankle.

# Hip Injuries



For a patient with a hip injury, bind the legs together.

# Femoral Shaft Fracture

---

- Patient assessment
  - Intense pain
  - Possibly open fracture
  - Injured limb may be shortened

*continued on next slide*

# Femoral Shaft Fracture

---

- Patient care
  - Control bleeding.
  - Manage for shock.
  - Provide oxygen.
  - Assess distal CSM.
  - Apply traction splint.
  - Reassess distal CSM.



# Pediatric Note

---

- When traction-splinting thigh injuries in children, be sure to use appropriately-sized splints.
- Infants and children with fractured femurs often have injuries to internal organs.

# Knee Injury

---

- Patient assessment
  - Pain and tenderness
  - Swelling
  - Deformity with swelling
- Patient care
  - Assess distal CSM.
  - Immobilize in current position.
  - Reassess distal CSM.

# Tibia or Fibula Injury

---

- Patient assessment
  - Pain and tenderness
  - Swelling
  - Possible deformity
- Patient care
  - Apply air-inflated splint.
  - Immobilize fracture using two rigid board splits.
  - Apply single splint with ankle hitch.

# Ankle or Foot Injury

---

- Patient assessment
  - Pain
  - Swelling
  - Possible deformity

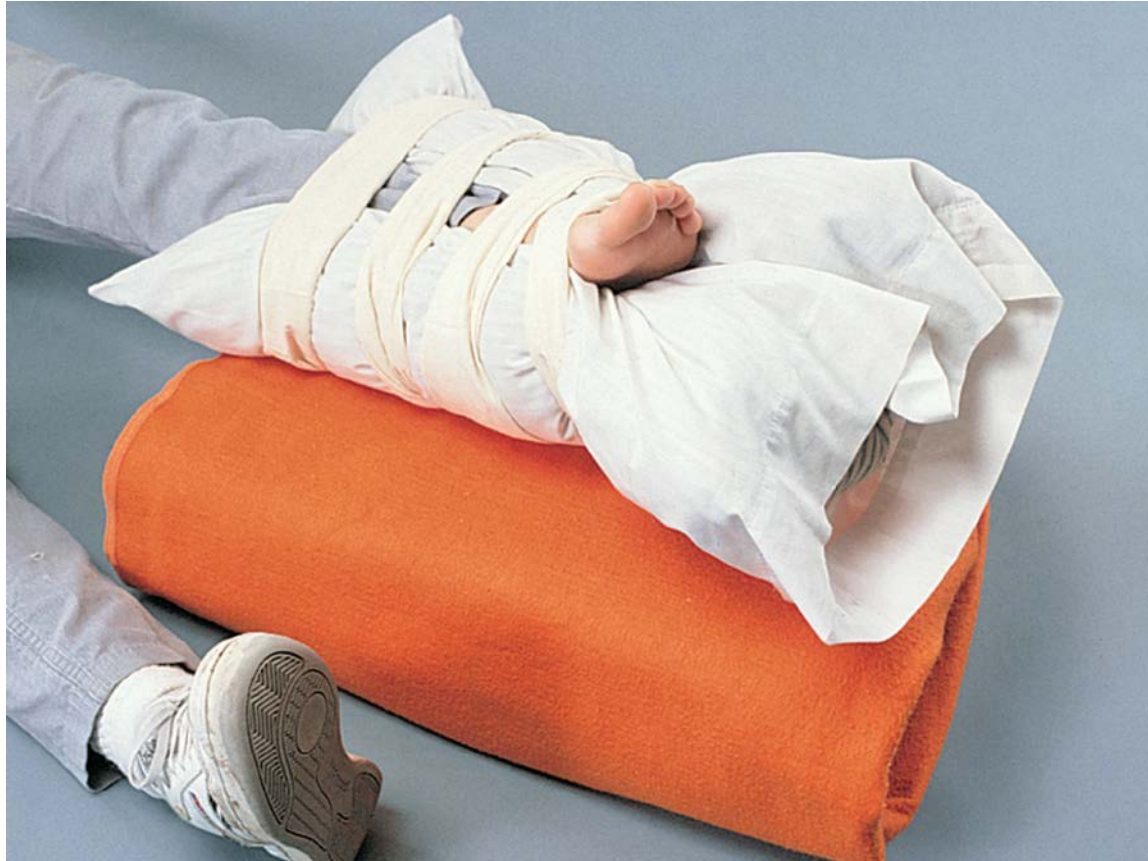*continued on next slide*

# Ankle or Foot Injury

---

- Patient care
  - Assess distal CSM.
  - Stabilize limb.
  - Lift limb.
  - Place cravats under ankle.
  - Lower limb into pillow.
  - Tie pillow around ankle.

# Ankle/Foot Injury



A pillow splint may be used for an injured ankle.

# Ankle or Foot Injury

---

- Patient care
  - Tie fourth cravat at arch of foot.
  - Elevate with second pillow or blanket.
  - Reassess distal CSM.
  - Care for shock if needed.
  - Apply ice pack as needed.

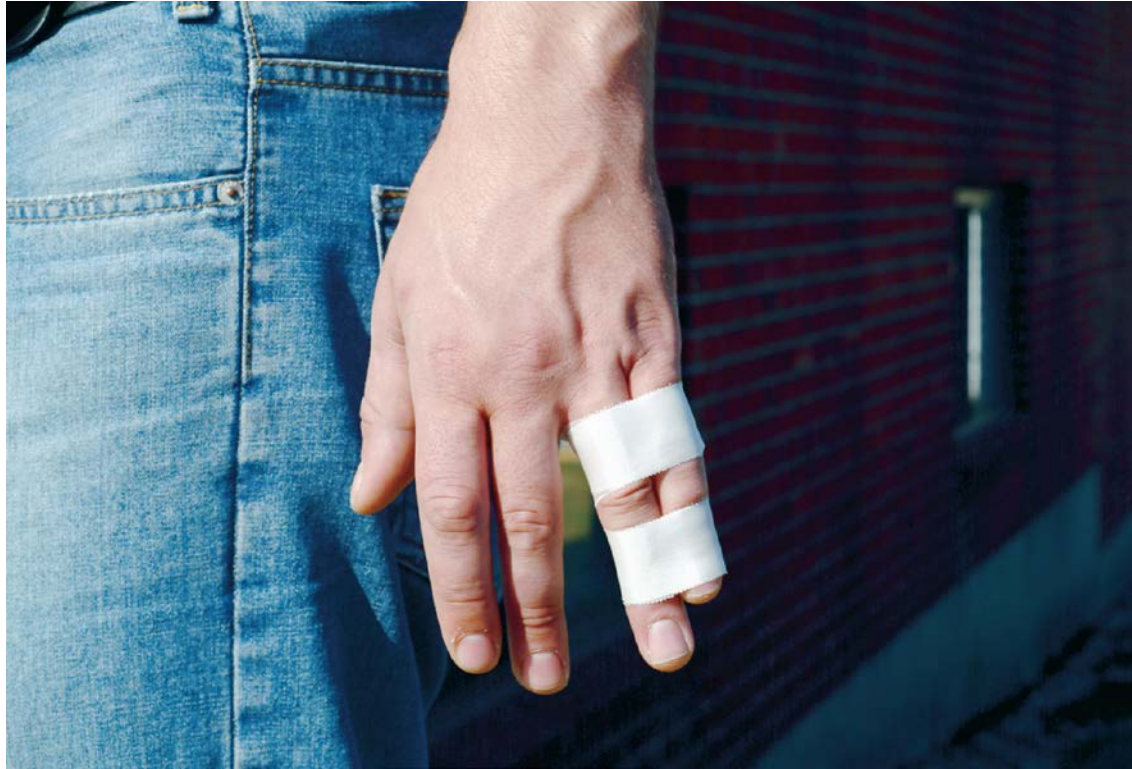# Forearm, Wrist, and Hand Injuries

---

- Signs
  - Forearm
    - Deformity and tenderness
  - Wrist
    - Deformity and tenderness
  - Hand
    - Deformity and pain
    - Dislocated fingers

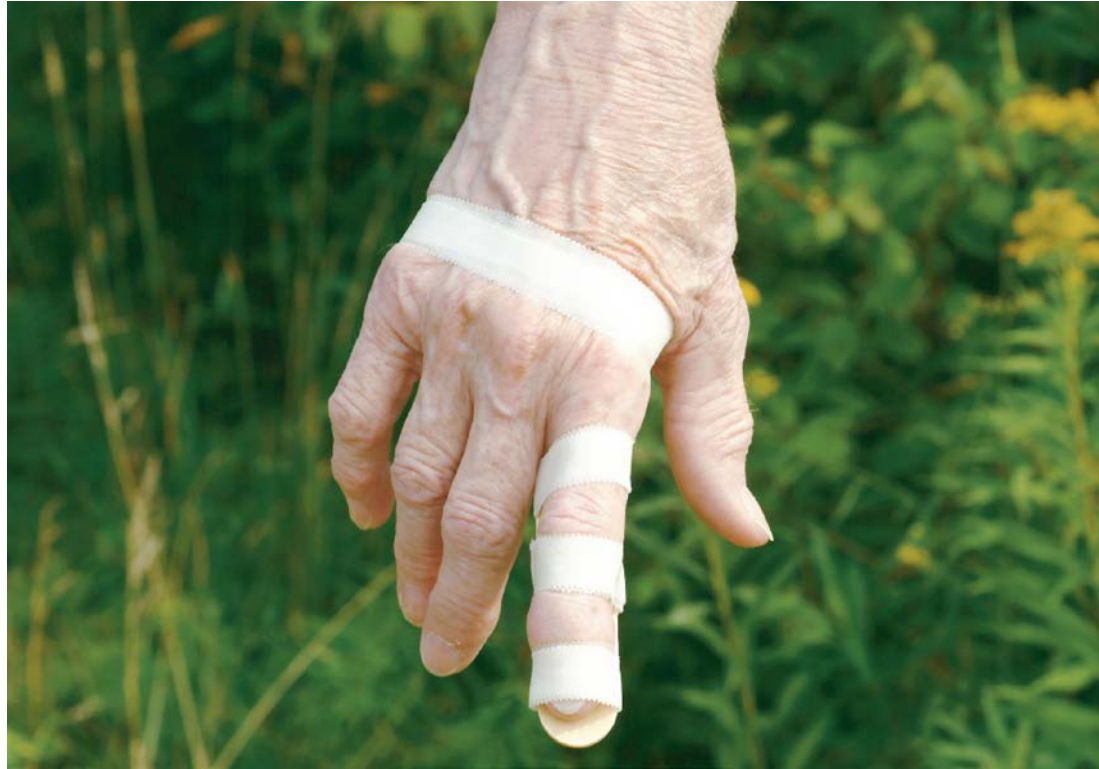

# Splinting Forearm, Wrist, and Hand Injuries



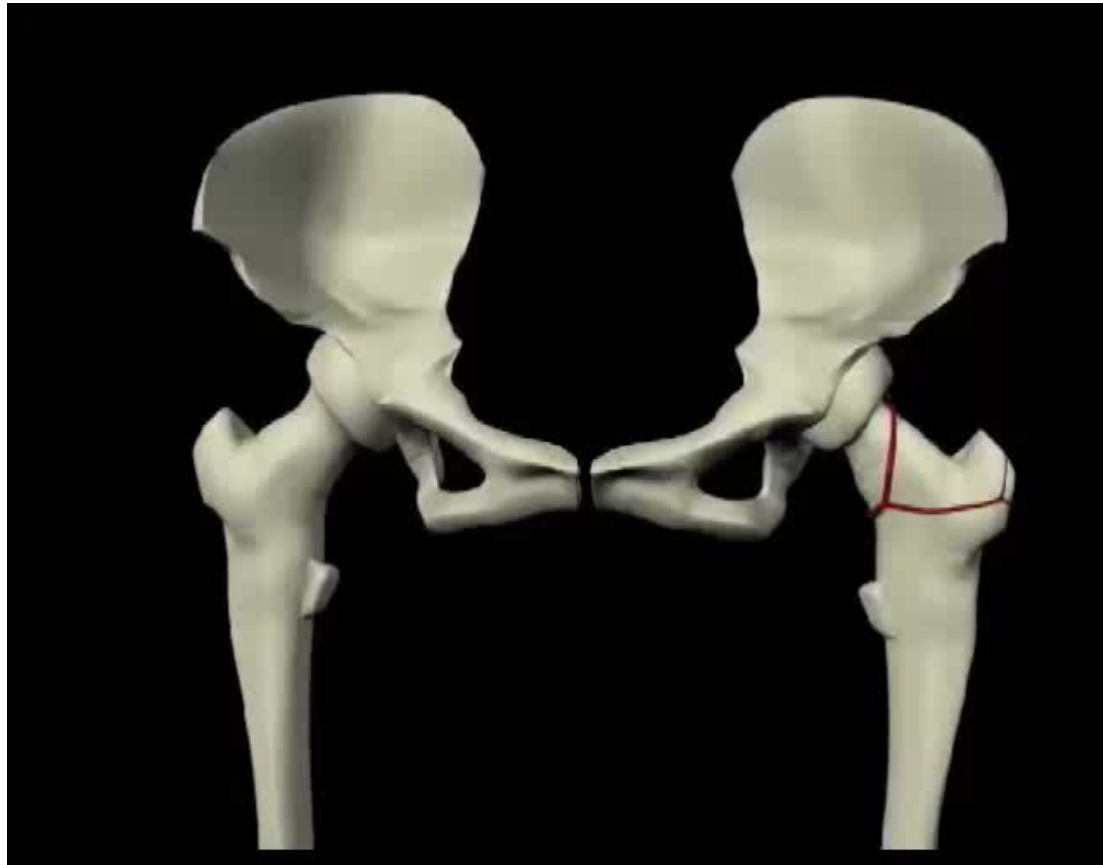
**SPLINTING A FINGER:** An injured finger can be taped to an adjacent uninjured finger, which acts as a splint to the injured finger. Or an injured finger can be splinted with a tongue depressor. Some emergency department physicians prefer that care to an injured finger be limited to a wrap of soft bandages. Do not try to "pop" dislocated fingers back into place.

# Splinting Forearm, Wrist, and Hand Injuries



**SPLINTING A FINGER:** An injured finger can be taped to an adjacent uninjured finger, which acts as a splint to the injured finger. Or an injured finger can be splinted with a tongue depressor. Some emergency department physicians prefer that care to an injured finger be limited to a wrap of soft bandages. Do not try to "pop" dislocated fingers back into place.

# Hip Fractures Animation



Click on the screenshot to view an animation on the subject of hip fractures.

[Back to Directory](#)

# Chapter Review

# Chapter Review

---

- Bones bleed. Fractures cause blood loss within the bone as well as from tissue damage around the bone ends. Serious or multiple fractures can cause shock.
- Splinting of long-bone fractures involves immobilizing the bone ends as well as the adjacent joints.

*continued on next slide*

# Chapter Review

---

- Splinting protects the patient from further injury, reduces pain, and helps control bleeding.
- You may need to be creative while splinting. There are many correct ways to splint the same extremity.
- Injuries to bones and joints should be splinted prior to moving the patient.

*continued on next slide*

# Chapter Review

---

- If patient has multiple trauma or appears to have shock (or a significant potential for shock), do not waste time splinting individual fractures. Place patient on long spine board and secure limbs to board. Splint individual fractures en route if time and priorities allow.

# Remember

---

- Bones, joints, muscles, cartilage, tendons, and ligaments make up the musculoskeletal system.
- Bones provide the body with structure, store metabolic materials, and produce red blood. Joints are the places where bones articulate to create movement.

*continued on next slide*



# Remember

---

- Fractures, dislocations, sprains, and strains are musculoskeletal injuries that are caused by direct force, indirect force, and twisting force. Injuries should be splinted prior to moving the patient.

*continued on next slide*

# Remember

---

- A closed extremity injury is one in which the skin has not been broken. An open extremity injury is one in which the skin has been broken.
- Pelvic fractures and femoral shaft fractures often indicate more severe internal injuries.

*continued on next slide*

# Remember

---

- EMTs must learn specific techniques for immobilizing particular injuries but at the same time must foster creativity while applying the general rules of splinting.

# Questions to Consider

---

- Have I fully addressed life threats and maintained my priorities even in the presence of a grossly deformed extremity?
- Does the patient have an injury that requires splinting?

*continued on next slide*

# Questions to Consider

---

- Does the patient have multiple fractures, multiple trauma, or shock?
- Does the patient have adequate CSM distal to the musculoskeletal injury?
- Should I align the angulated extremity fracture?

# Critical Thinking

---

- Patients who suffer fractures can be in extreme pain. Pain can cause anxiety and elevated pulse rates. How could you differentiate between a patient with a rapid pulse and anxiety from pain versus a patient with rapid pulse and anxiety from shock?